Int. J. Oral Maxillofac. Surg. 2011; 40: 679–684
doi:10.1016/j.ijom.2011.02.014, available online at http://www.sciencedirect.com

International Journal of
Oral & Maxillofacial Surgery

Clinical Paper
Craniofacial Surgery

Additional orthognathic surgery following Le Fort III and monobloc advancement

E. Nout, M. J. Koudstaal, E. B. Wolvius, K. G. H. Van der Wal
Department of Oral and Maxillofacial Surgery - Erasmus MC University Medical Center Rotterdam, The Netherlands

E. Nout, M. J. Koudstaal, E. B. Wolvius, K. G. H. Van der Wal: Additional orthognathic surgery following Le Fort III and monobloc advancement. Int. J. Oral Maxillofac. Surg. 2011; 40: 679–684.

Abstract. Severe midface hypoplasia in patients with various craniofacial anomalies can be corrected with Le Fort III or monobloc advancement. Often additional corrective orthognathic surgery is indicated to achieve Class I occlusion and a normal inter-jaw relationship. This study evaluated the incidence of, and the surgical indications for, secondary orthognathic surgery following Le Fort III/ monobloc advancement. The total study group consisted of 41 patients: 36 patients with Le Fort III advancement and 5 patients with monobloc advancement. Seven patients underwent additional orthognathic surgery. Of the resulting 18 non-operated patients older than 18 years at the end of follow-up, Class I occlusion was observed in 11 patients. In the remaining patients malocclusions were dentally compensated with orthodontic treatment. None of the patients was scheduled for additional orthognathic surgery due to the absence of functional complaints and/or resistance to additional surgery. Le Fort III and monobloc advancement aim to correct skeletal deformities on the level of zygoma, orbits, nasal area and forehead, but Class I occlusion is frequently not achieved. Additional orthognathic surgery is often indicated in patients undergoing Le Fort III or monobloc advancement. Naso-endoscopic analysis of the upper airway and the outcomes of sleep studies may influence the orthognathic treatment plan.

Key words: Le Fort; distraction osteogenesis; monobloc; orthognathic; obstructive sleep apnea; craniofacial.

Accepted for publication 10 February 2011
Available online 12 March 2011

Midface hypoplasia in syndromal craniosynostosis (SCS) patients and non-syndromal patients can be associated with upper airway obstruction, ocular proptosis, Class III malocclusion and facial distortion leading to psychosocial problems[15]. There seems to be a relation between obstructive sleep apnea (OSA) and raised intracranial pressure (ICP)[17]. Ideally, Le Fort III and monobloc advancement is planned when skeletal maturity is reached but in cases with OSA, raised ICP and ocular related pathology (inability of complete eyelid closure, (sub-)luxation) surgical intervention can not be postponed until skeletal maturity.

Since the focus of this early surgery is concentrated on this acute pathology, relative indications, such as Class III malocclusion and facial aesthetic disharmony, may not be corrected. In addition, the literature reports a severely diminished intrinsic horizontal growth potential of the midface in SCS patients regardless of surgery[7,11,14]. Continuing growth of the mandible may cause pseudorelapse so some degree of overcorrection in growing patients is advised. Nevertheless, correction of the deformity on the occlusal level may not be treated with Le Fort III or monobloc advancement. Frequently, additional orthognathic surgery is indicated later. Various suggestions are reported in literature[2,7,12,14]. There are no clinical guidelines regarding the ideal timing and planning of these surgical procedures and

0901-5027/070679 + 06 $36.00/0

the related orthodontic treatment. The aim of this retrospective study is to report the experience with additional orthognathic surgery as the final procedure to achieve a functional inter-jaw relationship and a Class I occlusion following Le Fort III and monobloc advancement.

Materials and methods

The study group consisted of 41 patients with cleft and various craniofacial anomalies. All patients who underwent Le Fort III or monobloc advancement between 1999 and 2009 were included. 38 SCS patients (16 with Apert syndrome, 17 with Crouzon syndrome and 5 with Pfeiffer syndrome) were reviewed of whom 33 underwent Le Fort III advancement and 5 underwent monobloc advancement. There were 2 patients with frontonasal dysplasia. Besides these patients there was one patient with both a bilateral cleft-lip-alveolus-palate and a median cleft. The last patient had both conditions. 7 patients underwent a conventional Le Fort III osteotomy, 29 patients underwent a Le Fort III distraction osteogenesis (DO) procedure and all monobloc patients underwent DO. In one patient who underwent Le Fort III DO and one patient who underwent conventional Le Fort III osteotomy, simultaneous with the Le Fort III osteotomy, a Le Fort I osteotomy was performed. DO was performed using either internal (14 patients, including all monobloc patients) or external distractors (20 patients). The Marchac–Arnaud distraction system (KLS Martin, Tuttlingen, Germany) was used for internal DO. External DO was achieved using the RED II halo frame (KLS Martin, Tuttlingen, Germany) or external midface distractor (Synthes, Solothurn, Switzerland).

Indications for primary surgery were classified as absolute or relative. Absolute indications were moderate or severe OSA (oxygenation desaturation index > 5 and/or patients requiring tracheotomy), raised ICP and exorbitism including persistent exposure keratitis and (sub-)luxation of the globe. Relative indications were impaired aesthetic appearance, exorbitism without clinical significance, Class III malocclusion and psychosocial considerations.

Le Fort III and monobloc distraction protocol

A latency period of 7 days postoperatively was applied to all patients irrespective of age or degree of advancement. The distraction rate was 1 mm per day for the Le Fort III distraction and 0.5 mm for the monobloc distraction. Distraction time was based on the desired advancement. For the Le Fort III patients vector modifications took place during distraction when necessary. Distraction was terminated when a normal malar and nasal projection was achieved and exorbitism was corrected. After Le Fort III distraction patients underwent a consolidation period of 3 months. The internal devices in the monobloc distraction cases were removed after 6 months of consolidation.

Indications for secondary orthognathic surgery

Indications for additional orthognathic surgery were assessed by clinical evaluation of the occlusion and profile and cephalometric analysis using standardized lateral skull radiographs. Clinical examination was performed by an orthodontist and a maxillofacial surgeon. In case of residual OSA, naso-endoscopic examination was performed by an otolaryngologist to identify the level of upper airway obstruction. Indications for additional orthognathic surgery were frontal open bite, Class II or III malocclusion, transverse discrepancy, evident crowding and residual OSA.

Data collection

Data were collected retrospectively from the patients' medical records. Indications, age at primary operation, age at secondary orthognathic surgery (if performed) and interval between primary and secondary surgery were evaluated. In all patients completion of skeletal growth was defined at the age of 18 years.

Results

Data are summarized in Table 1. In the total group the mean age at operation was 13.9 years (standard deviation (SD) 6.0). The mean age was 14.5 years (SD 5.3) in the Le Fort III group and 9.2 years (SD 8.8) in the monobloc patients. The patients with an absolute indication ($n = 21$) were on average operated on at a younger age (mean 11.1, SD 6.4 years) compared with patients undergoing surgery because of a relative indication ($n = 20$, mean = 16.8, SD 3.8). In the total patient cohort 17 (13 Le Fort III patients and 4 monobloc patients) of the 41 patients (41.5%) were younger than 18 years at the end of the follow-up period. The mean follow-up period was 4.8 years (SD 3.0).

Additional orthognathic surgery

7 patients underwent additional orthognathic surgery (Table 1). In the total group the mean age at additional orthognathic surgery was 19.6 years (SD 2.4). Both over- and under-correction at the occlusal level was noted. In case of Class III malocclusion Le Fort I advancement was the treatment of choice ($n = 3$). In two cases of overcorrection, bimaxillary correction was planned. In one patient, mandibular advancement was indicated to correct the deformity. In the Le Fort III group, 3 patients underwent a Le Fort I osteotomy, two patients underwent bimaxillary advancement and one patient underwent surgically assisted rapid maxillay expansion (SARME). In the monobloc group one patient underwent a SARME before the monobloc and a bilateral sagittal split osteotomy (BSSO) after the monobloc. In this patient naso-endoscopy revealed obstructions at the level of the base of the tongue and at the deviated nasal septum. A nasal septum correction was performed simultaneously with the BSSO and removal of the internal monobloc distractors.

Additional orthognathic surgery was performed on average 34 months (SD 34.9) after primary surgery. Three patients with initial surgery before the age of 18 years underwent additional orthognathic surgery; four patients with initial surgery after the age of 18 years underwent additional orthognathic surgery.

Clinical evaluation of the resulting 18 non-operated patients who were older than 18 years of age at the end of the follow-up period, revealed Class I occlusion in 11 patients. Of the remaining patients, 3 showed Class II malocclusion and 4 showed Class III malocclusion. By means of orthodontic treatment, all malocclusions were dentally compensated. In addition, 5 patients showed a frontal open bite and 2 showed a bilateral open bite. None of these patients was scheduled for additional orthognathic surgery due to the absence of functional complaints and resistance to additional surgery.

Discussion

In the multidisciplinary treatment of patients with SCS and other non-syndromal patients, Le Fort III or monobloc advancement is often the treatment of choice to address the problems emerging from marked retrusion of the midface. In the case of absolute indications, surgery is often performed at a young age. The focus of this surgery is to resolve OSA, raised ICP or severe exophthalmus. The timing

Table 1. Overview of patient cohort subdivided according to surgical intervention and craniofacial anomaly. All patients underwent distraction osteogenesis except for the patients marked with an asterisk who underwent conventional Le Fort III osteotomy.

Patient	Syndrome	Indication for primary surgery	Young age at time of primary surgery (years)	Orthognathic surgery	Indication for orthognathic surgery	Young age at time of orthognathic surgery (years)	Young age at end of follow-up (years)	No orthognathic surgery performed at the end of this study due to
LF III								
1	Apert	Absolute	16				20	Class II comp; open bite
2	Apert	Absolute	12				17	Young age
3	Apert	Relative	20				25	Class II comp; open bite
4	Apert	Relative	15				19	Class III comp; open bite
5	Apert	Relative	18				22	Class I
6	Apert	Relative	19	Bimaxillary advancement	Class II	20	23	–
7	Apert	Absolute	7	SARME	Crowding dentition maxilla	15	16	–
8	Apert	Relative	24				27	Class I
9	Apert	Absolute	14				15	Young age
10	Apert	Absolute	19	Le Fort I	Class III	19	23	–
11	Apert	Relative	16	Le Fort I	Class III	20	27	–
12	Apert	Absolute	12				19	Class III comp
13	Apert	Relative	19				27	Class I
14	Crouzon	Relative	17				23	Class I
15	Crouzon	Relative	15	Le Fort I	Class III	21	22	–
16	Crouzon	Absolute	11				16	Young age
17	Crouzon	Absolute	16				21	Class III comp
18	Crouzon	Absolute	13				17	Young age
19	Crouzon	Relative	14				17	Young age
20	Crouzon	Relative	8				10	Young age
21	Crouzon	Absolute	6				16	Young age
*22	Crouzon	Absolute	3				15	Young age
23	Crouzon	Relative	19	Bimaxillary advancement	Class II	19	21	–
24	Crouzon	Absolute	11				11	Young age
25	Crouzon	Relative	8				10	Young age
26	Crouzon	Relative	18				23	Class I
27	Crouzon	Relative	18				27	Class III; open bite
*28	Crouzon	Absolute	21				24	Class I
*29	Pfeiffer	Relative	18				25	Class I
30	Pfeiffer	Relative	14				19	Class II; open bite
*31	Pfeiffer	Absolute	7				11	Young age
*32	Pfeiffer	Absolute	1				11	Young age
33	Pfeiffer	Relative	20				26	Class I
*34	NMD	Relative	17				19	Class I; open bite
*35	NMD	Relative	19				30	Class I
36	CLAP	Absolute	18				22	Class I; open bite
Monobloc								
1	Apert	Absolute	23	BSSO and nasal septum correction	Class II	23	24	–

Table 1 (*Continued*)

Patient	Syndrome	Indication for primary surgery	Young age at time of primary surgery (years)	Orthognathic surgery	Indication for orthognathic surgery	Young age at time of orthognathic surgery (years)	Young age at end of follow-up (years)	No orthognathic surgery performed at the end of this study due to
2	Apert	Absolute	2				3	Young age
3	Apert	Absolute	12				12	Young age
4	Crouzon	Absolute	7				11	Young age
5	Crouzon	Absolute	2				5	Young age

NMD = nasomaxillary dysplasia.
CLAP = cleft-lip-alveolus-palate.
Young age = patient younger than 18 years.

of surgery is dictated by the onset of functional problems[15]. Due to a diminished syndrome-related intrinsic anterior growth potential of the midface, little forward growth is expected postsurgically[1,7,11,14]. This, together with the unaffected growth of the mandible, might cause (pseudo-)relapse at an older age requiring additional (orthognathic) surgery. A substantial risk of recurrent OSA is also present. Cases with pressing indications in which Le Fort III or monobloc DO is performed at a very young age, run the risk of residual raised ICP or OSA during growth. In these cases often a second Le Fort III or monobloc advancement is indicated, which is unfavourable. In cases of raised ICP in young patients, fronto-orbital advancement (FOA) used to be advocated; the treatment protocol in the authors' craniofacial centre is posterior vault expansion. FOA negatively influences the patients' aesthetic appearance and hinders possible additional Le Fort III or monobloc interventions.

To minimize the risk of additional orthognathic surgery, the authors try to advance the midface or monobloc segment as much forward as possible in young patients. Long-term studies report little or no relapse after both conventional Le Fort III osteotomy and Le Fort III DO, rendering both procedures to be stable[4,7,10,13,14]. DO in these cases is the treatment of choice to allow for these large advances. In case of OSA, the midface or monobloc segment is advanced forward until the OSA is corrected. With regard to monobloc advancement, a comparative study showed less relapse and greater advancement in patients undergoing monobloc DO compared with conventional monobloc advancement after 2 year follow-up[2]. Monobloc DO is associated with less morbidity[2,6,9]. In SCS patients with severe midface concavity or flattening, facial bipartition advancement using DO should be considered. This gives the surgeon the opportunity to advance the central portion of the face more than the lateral sides and thereby 'unflatten' this otherwise characteristic stigma of the syndrome[18]. This could result in a relatively higher increase of upper airway volume than with the traditional midface advancement. The literature reports stable results using both external and internal distractors[3,6,18]. By widening the maxilla with facial bipartition, additional SARME might be prevented in the future and less postoperative open bite may occur.

In the study group, 7 patients needed additional orthognathic surgery. Of these, 3 underwent Le Fort III advancement before completion of growth. In the study group, 17 patients did not complete growth during the course of this study so some of them might need additional orthognathic surgery later in life. Theoretically, the three patients who underwent monobloc advancement, aged 2 years (two patients) and 7 years, are especially prone to additional surgery. Therefore, no exact percentages can be reported in this study.

Four patients (3 Le Fort III patients and 1 monobloc patient) underwent additional orthognathic surgery at maturity to achieve Class I occlusion. In one patient additional mandibular advancement and nasal septum correction was indicated to treat the residual OSA at the level of the oro-/hypopharynx and nasal cavity respectively (Fig. 1). In a patient with a preoperative diagnosis of severe OSA, postoperative naso-endoscopy revealed an additional obstruction of the upper air-

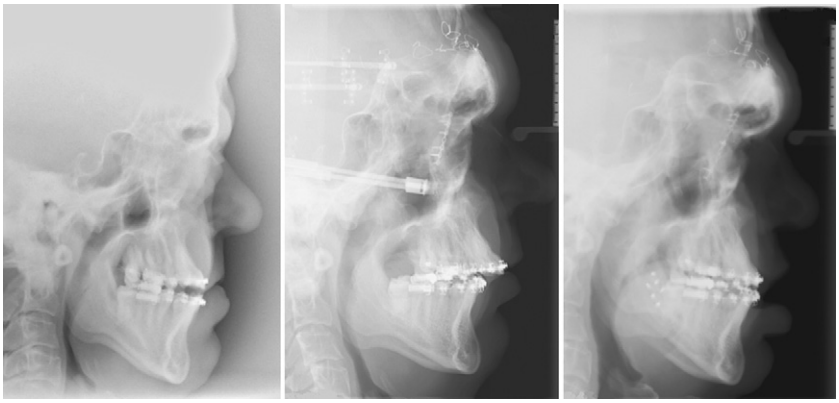

Fig. 1. (A) Preoperative lateral skull radiograph of a patient with Apert syndrome showing the midface hypoplasia. (B) Lateral skull radiograph after monobloc advancement with the distractors still in place. Residual OSA at the level of the oro-/hypopharynx and nasal cavity was revealed by naso-endoscopy. Additional BSSO and nasal septum correction was indicated. (C) Postoperative lateral skull radiograph.

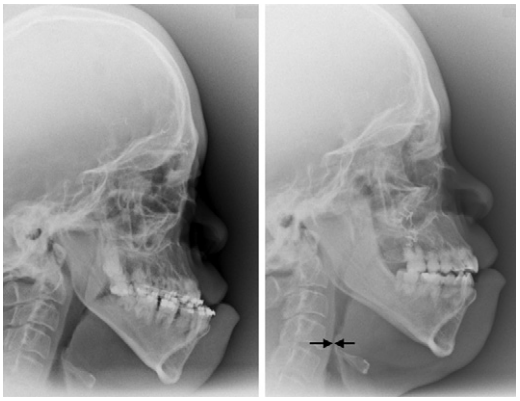

Fig. 2. Lateral skull radiographs of a patient with Crouzon syndrome (A) before and (B) after Le Fort III DO. Naso-endoscopy revealed residual OSA on level of the oro-/hypopharynx which can be seen in B (arrow).

way at the level of the oro-/hypopharynx causing residual OSA (Fig. 2). Ideally, this obstruction should have been identified before the primary surgery. The advancement of the midface could have been attuned to the additional mandibular advancement needed to alleviate the obstruction at the level of the oro-/hypopharynx.

During the Le Fort III and monobloc procedures the nasal septum is osteotomized, which may result in septum deviation and upper airway obstruction. Naso-endoscopic screening by an experienced otolaryngologist in cases of OSA is advocated to identify the level of upper airway obstruction. Naso-endoscopic analysis of the upper airway may influence the orthognathic treatment plan. This analysis together with polysomnography should be a standard part of the preoperative orthognathic protocol.

Most of these cases in which midface advancement is indicated after completion of growth, demonstrate that surgical correction focuses on correction of the deformity on the level of the orbits and zygoma. In a substantial number, Class I occlusion was achieved simultaneously with the correction of the deformity of the midface. Postoperatively, Angle Class II or III occlusion may persist and might need correction after consolidation of the initial surgery. SCS patients, especially patients with Crouzon syndrome, are frequently associated with a frontal open bite that is likely to persist after Le Fort III or monobloc advancement. In case of functional complaints an additional Le Fort I osteotomy with intrusion of the dorsal part of the maxilla together with a BSSO advancement is the treatment of choice to correct the frontal open bite (Fig. 3). In case of a pronounced gummy smile, which can arise after Le Fort III DO, the same modality can be used to reduce it. The authors achieved good results by combining Le Fort III and I osteotomies in one patient with nasomaxillary dysplasia (conventional Le Fort III and I osteotomies) and one patient with cleft-lip-alveolus-palate (Le Fort III and I DO). This technique gives good results on the level of the midface and allows correction of the occlusion at the same time. Although the number of patients undergoing this technique is small in this series, the authors' positive experience is supported by previous reports. In 1969, Obwegeser was the first to report on the possibility of combining Le Fort III and I osteotomies[16]. Excellent results using this technique were noted by Freihofer in 1973[8]. Besides the combination of Le Fort III and I osteotomy, Freihofer also reported positive results from combining Le Fort III and II osteotomy, or Le Fort III and II osteotomy including a correction of the telecanthus and, if desired, with an additional Le Fort I osteotomy. A literature search revealed only a few reports on combination osteotomies. Recently, Cheung et al. reported good results using Le Fort III and I combination osteotomies in three patients[5]. Satoh et al. published similar results using this technique in 4 cases including one patient with Apert syndrome who was aged 13 years at the time of surgery[19]. Since combination osteotomies seem to yield good results in adult patients, the technique of DO seems to be indicated for patients who have not yet completed growth, to advance the segment over larger distances including the required overcorrection.

A substantial number of patients with SCS are characterized by a varying degree of mental retardation, for example patients with Apert syndrome (14 patients in this study group). Mental retardation can be associated with diminished coping abilities and compliance. These problems often give rise to a suboptimal end result of the initial treatment. In these cases, additional orthognathic surgery, although often indicated, might not be indicated. In these patients any correction of the facial disharmony can be considered an improvement on the preoperative situation.

In conclusion, Le Fort III and monobloc advancement aim to correct the deformities at the level of zygoma, orbits and nasal areas, respectively. Frequently Class I occlusion is not achieved. This makes Le Fort III and monobloc advancement indefinite procedures, especially when performed during early childhood. Additional orthognathic surgery is often indicated in patients undergoing Le Fort III or monobloc advancement. Naso-endoscopy of the upper airway and continuing sleep studies in patients with persistent OSA are recommended, the outcomes of which may influence orthognathic treatment. Long-term follow-up studies are necessary to determine the exact incidence of additional orthognathic surgery after midface or monobloc advancement. For adult

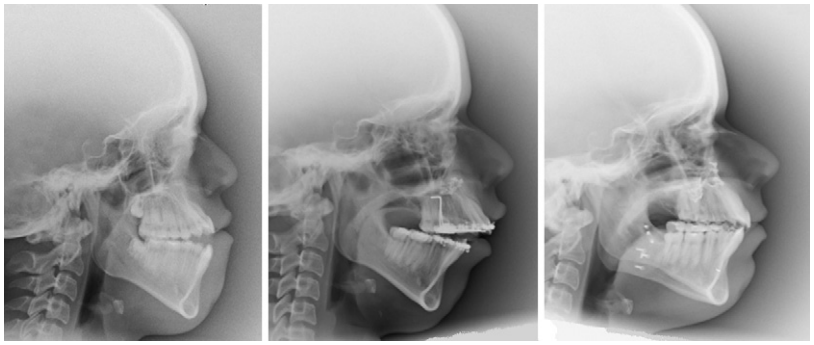

Fig. 3. Patient with Crouzon syndrome with a considerable frontal open bite preoperatively (A). After Le Fort III DO the frontal open bite becomes more evident and Class II malocclusion is present (B). After Le Fort I osteotomy with intrusion of the dorsal part of the maxilla together with a BSSO advancement, a stable Class I occlusion was attained (C).

patients with completed skeletal growth, combination osteotomies, such as Le Fort III combined with Le Fort I, should be considered.

Funding

None.

Conflict of interest

None declared.

Ethical approval

Not required.

References

1. Bachmayer DI, Ross RB, Munro IR. Maxillary growth following LeFort III advancement surgery in Crouzon, Apert, and Pfeiffer syndromes. Am J Orthod Dentofacial Orthop 1986: **90**: 420–430.
2. Bradley JP, Gabbay JS, Taub PJ, Heller JB, O'Hara CM, Benhaim P, Kawamoto: 1585–1597.
3. Bradley JP, Levitt A, Nguyen J, Raposo CE, Jarrahy R, Katchikian HV, Kawamoto HK. Roman arch, keystone fixation for facial bipartition with monobloc distraction. Plast Reconstr Surg 2008: **122**: 1514–1523.
4. Cedars MG, Linck II DL, Chin M, Toth BA. Advancement of the midface using distraction techniques. Plast Reconstr Surg 1999: **103**: 429–441.
5. Cheung LK, Ow A, Chua HD. Simultaneous modified oblique Le Fort III and segmentalized Le Fort I osteotomies. J Oral Maxillofac Surg 2010: **68**: 915–923.
6. Cohen SR, Boydston W, Hudgins R, Burstein FD. Monobloc and facial bipartition distraction with internal devices. J Craniofac Surg 1999: **10**: 244–251.
7. Fearon JA. Halo distraction of the Le Fort III in syndromic craniosynostosis: a long-term assessment. Plast Reconstr Surg 2005: **115**: 1524–1536.
8. Freihofer Jr HP. Results after midface-osteotomies. J Maxillofac Surg 1973: **1**: 30–36.
9. Gosain AK, Santoro TD, Havlik RJ, Cohen SR, Holmes RE. Midface distraction following Le Fort III and monobloc osteotomies: problems and solutions. Plast Reconstr Surg 2002: **109**: 1797–1808.
10. Kaban LB, Conover M, Mulliken JB. Midface position after Le Fort III advancement: a long-term follow-up study. Cleft Palate J 1986: **23**: 75–77.
11. Kreiborg S, Aduss H. Pre- and postsurgical facial growth in patients with Crouzon's and Apert's syndromes. Cleft Palate J 1986: **23**: 78–90.
12. Marchac D, Renier D, Broumand S. Timing of treatment for craniosynostosis and facio-craniosynostosis: a 20-year experience. Br J Plast Surg 1994: **47**: 211–222.
13. McCarthy JG, La Trenta GS, Breitbart AS, Grayson BH, Bookstein FL. The Le Fort III advancement osteotomy in the child under 7 years of age. Plast Reconstr Surg 1990: **86**: 633–646 discussion 647–639.
14. Meazzini MC, Mazzoleni F, Caronni E, Bozzetti A. Le Fort III advancement osteotomy in the growing child affected by Crouzon's and Apert's syndromes: presurgical and postsurgical growth. J Craniofac Surg 2005: **16**: 369–377.
15. Nout E, Cesteleyn LL, van der Wal KG, van Adrichem LN, Mathijssen IM, Wolvius EB. Advancement of the midface, from conventional Le Fort III osteotomy to Le Fort III distraction: review of the literature. Int J Oral Maxillofac Surg 2008: **37**: 781–789.
16. Obwegeser HL. Surgical correction of small or retrodisplaced maxillae. The ''dish-face'' deformity. Plast Reconstr Surg 1969: **43**: 351–365.
17. Peter L, Jacob M, Krolak-Salmon P, Petitjean T, Bastuji H, Grange JD, Vighetto A. Prevalence of papilloedema in patients with sleep apnoea syndrome: a prospective study. J Sleep Res 2007: **16**: 313–318.
18. Ponniah AJ, Witherow H, Richards R, Evans R, Hayward R, Dunaway D. Three-dimensional image analysis of facial skeletal changes after monobloc and bipartition distraction. Plast Reconstr Surg 2008: **122**: 225–231.
19. Satoh K, Mitsukawa N, Hosaka Y. Dual midfacial distraction osteogenesis: Le Fort III minus I and Le Fort I for syndromic craniosynostosis. Plast Reconstr Surg 2003: **111**: 1019–1028.

Address:
Erik Nout
Erasmus MC University Medical Center Rotterdam
Department of Oral and Maxillofacial Surgery
Room D-230
Dr Molewaterplein 40
3000 CA Rotterdam
The Netherlands
Tel: +31 10 703 33 02
Fax: +31 10 703 30 98
E-mail: e.nout@erasmusmc.nl